

Review article

Ocular motor assessment in concussion: Current status and future directions

Rachel E. Ventura^{a,*}, Laura J. Balcer^{a,b,c}, Steven L. Galetta^{a,c}, Janet C. Rucker^a^a New York University School of Medicine, Department of Neurology, United States^b New York University School of Medicine, Department of Population Health, United States^c New York University School of Medicine, Department of Ophthalmology, United States

ARTICLE INFO

Article history:

Received 4 November 2015

Received in revised form 25 November 2015

Accepted 7 December 2015

Available online 9 December 2015

Keywords:

Concussion

Vision

Testing

Head impact

Neuro-ophthalmology

ABSTRACT

Mild head injury such as concussions and subconcussive repetitive impact may lead to subtle changes in brain function and it is imperative to find sensitive and reliable tests to detect such changes. Tests involving the visual system, in particular eye movements, can incorporate higher cortical functioning and involve diffuse pathways in the brain, including many areas susceptible to head impact. With concussions, the clinical neuro-ophthalmic exam is important for detecting abnormalities in vergence, saccades, pursuit, and visual fixation. On the sidelines, the King–Devick test has been used as a visual performance measure that incorporates eye movements and increases the sensitivity in detecting possible concussions in conjunction with standard sideline tests of cognition, symptom checklists, and balance. Much promise lies in the eye movement laboratory to quantitate changes in saccades and pursuit with concussions using video-oculography. A combination of eye movement tasks coupled with neuroimaging techniques and other objective biomarkers may lead to a better understanding of the anatomical and physiological consequences of concussion and to better understand the natural history of this condition.

© 2015 Elsevier B.V. All rights reserved.

Contents

1. Introduction	79
2. Methods	80
3. Eye movement abnormalities in concussion: the clinic	80
3.1. Ocular motor cranial nerve palsies	80
3.2. Convergence insufficiency	80
3.3. Saccades and smooth pursuit	81
3.4. Other visual abnormalities	81
4. Eye movement abnormalities in concussion: the eye movement laboratory	81
4.1. Saccades	81
4.2. Smooth pursuit	81
4.3. Video-oculography correlations with MRI	82
5. Eye movement abnormalities in concussion: the sidelines	83
5.1. Portable video-oculography	83
5.2. King–Devick (K–D) test for sideline assessment	83
6. Complex visuomotor tasks for return to play	83
7. Conclusions and future directions	85
References	85

1. Introduction

Concussion is increasingly recognized as a serious public health problem, with a growing need for sensitive tests to detect and evaluate

* Corresponding author at: NYU Langone Medical Center, Ambulatory Care Center, 240 East 38th Street, 18th floor, New York, NY 10016, United States.
E-mail address: rachel.ventura@nyumc.org (R.E. Ventura).

the resultant brain dysfunction. Ocular motor function incorporates circuits widely distributed in both cortical and subcortical structures, and provides a sensitive means of assessing pathways potentially damaged by concussion. This review will explore the ways that eye movements are compromised by concussion, as well as ocular motor-based tests helpful in concussion assessment on the sidelines, in the clinic, and in the laboratory.

The exact incidence of concussion remains unclear as estimations rely on emergency room presentations rather than outpatient visits, however one estimate is 3.8 million sports-related mild traumatic brain injuries (mTBI) annually in the United States [1–3]. The true incidence is likely much higher, as many individuals fail to report concussion. This is often because they are athletes who want to remain in play [4] or due to the false perception that concussion is benign. Further, milder repetitive sub-concussive head impacts that are common in sport are not captured in concussion incidence data, yet may cause structural brain and subtle functional performance changes [5–7].

Concussion has been defined as an impact to the head or body with accompanying neurological symptoms [8,9], although there is no clear consensus for its definition [10]. Concussion is often considered a subset of mild traumatic brain injury (mTBI), though the terms are often used interchangeably. Traditional diagnostic neuroimaging with head CT or conventional MRI typically fails to disclose any structural injury, though advanced neuroimaging techniques such as diffusion tensor imaging (DTI) have identified micro-architectural changes in white matter integrity [11–13]. Sub-concussive impacts during contact sports, as detected by measurements with helmet sensors (head impact telemetry system, or HITS), can also lead to white matter integrity alteration as assessed by DTI, as well as changes in metabolic profiles and functional MRI (fMRI) imaging [5,6,14–17].

In this review, the focus is on concussion, the mildest form of traumatic head injury that is due to head impact with an accompanying neurological symptoms and normal conventional neuroimaging. Appropriate return-to-play decisions after sports-related concussions are critical to prevent untoward sequelae that can occur after an athlete has repeated head trauma. After sustaining one concussion, an individual is three times more likely to have another concussion in the same season [18]. This places athletes at risk of developing the very rare second impact syndrome, which can be severely disabling or even fatal due to brain swelling after the second concussion [18–20]. Repeated mild head trauma has also been thought to potentially be associated with the long-term development of neurodegeneration [21–23].

Visual complaints are very common with concussion (Table 1). This is likely due to the fact that over half the brains circuits are involved in vision and eye movements [24] and many of these circuits are in regions particularly vulnerable to shear injury, such as the frontal lobes and just rostral to the midbrain [25–27]. Control of reflexive and voluntary eye movements, in particular, originates in circuits concentrated in frontal and parietal cortices, as well as diffusely distributed in subcortical nuclei. Probing these circuits with ocular motor testing provides insights into the effects of concussion.

2. Methods

Primary articles were identified using a pubmed search for combinations of “mild traumatic brain injury” or “head injury” or “concussion” and “ocular motor” or “eye movement” or “neuro-ophthalmology” or “vision” or “saccade” or “pursuit” or “vergence” or “accommodation” or “cranial nerve” or “King–Devick” or “visuomotor” published in print or electronically from 1/1/1995 to 9/1/2015 in English. Only articles on the efferent neuro-ophthalmological visual system were included. Only articles with clear inclusion criteria specifying patients with concussion or mild traumatic brain injury were included. Only articles on human subjects were included. 155 articles were retrieved from the search, 85 were excluded because they did not focus on the efferent visual system, an additional 25 were excluded because the subjects were

Table 1

Visual symptoms that were noted with increased frequency in one cohort of subjects with mTBI versus controls [Capo-Aponte], listed in decreasing frequency. Asterisks indicate symptoms significantly different in the small cohort of 20 patients versus 20 controls.

Visual symptoms in concussion
Lose place while reading*
Reduced or inefficient reading speed*
Light sensitivity*
Trouble keeping attention when reading
Words run together when reading*
Decreased reading comprehension*
Unable to read continuous text comfortably
Words blurring or coming in and out of focus*
Eye strain*
Visual fatigue
Difficulty scanning/navigating
Glare sensitivity
Visual motion sensitivity
Depth perception problem
Poor eye-hand coordination
Burn, itchy, watery eyes
Double vision
Seeing floor tilted
Aching eyes
Dizzy/nausea when reading
Head tilt/close one eye when reading
Bumping into objects/walls
Color vision problem
Problem with spatial relation among objects
Objects appear to move when not moving
Unable to see entire picture or its parts

not clearly defined to be mTBI or concussion, and 4 articles were done with non-human subjects, leaving 41 articles for our review. Classic papers on anatomy of eye movements and pathological changes in mTBI were also included, regardless of publication date.

3. Eye movement abnormalities in concussion: the clinic

Detailed neuro-ophthalmological studies evaluating the frequency of clinical ocular motor deficits in concussion are limited. The majority of neuro-ophthalmologic literature focuses on more severe traumatic brain injury due to motor vehicle accidents and assault. As attention has been drawn in clinical settings and the media to military combat-related mTBI and to sports-related mTBI, a vast body of literature with regard to visual and eye movement deficits has been published in the past decade.

3.1. Ocular motor cranial nerve palsies

Whereas cranial nerve abnormalities are common neuro-ophthalmologic manifestations of more severe forms of head trauma [28–31], they are less likely to occur in mTBI. This is particularly true of the third cranial nerve in the absence of a pre-existing structural abnormality, such as an underlying posterior communicating artery aneurysm [28,32]. Confirmation of the low incidence of ocular motor cranial nerve injury was provided in an analysis of 16,440 patients with mild head injury (defined as a Glasgow Coma Score of 14–15 regardless of head CT findings); 22 patients in that study had an ocular motor nerve palsy, only 7 of whom had normal head CT findings [33]. It would be distinctly rare for a concussion to produce a cranial nerve palsy and its occurrence should raise the possibility of a pre-existing mass lesion.

3.2. Convergence insufficiency

Convergence insufficiency has been reported to have a high prevalence in mTBI, ranging from 47–64% in combat-related mTBI patients and civilian populations undergoing optometric assessment [34–36]. However, the high frequency in such studies could reflect referral bias.

Convergence, a component of the near triad also including pupillary miosis and accommodation, involves adduction of both of the eyes in order to maintain binocular fusion on near targets. Convergence is most typically assessed by determining the near point of convergence (NPC), which is the distance at which patients can no longer maintain fusion. Szymanowicz and colleagues performed a detailed ocular assessment of 21 patients with mTBI and near work symptoms versus controls using infrared videography and dynamic retinoscopy, and found multiple abnormal vergence parameters including slower peak velocities and increased latencies for divergence and convergence as well as an increased NPC in the mTBI group [37]. When a Convergence Insufficiency Symptoms Survey was administered to a cohort of blast related mTBI patients versus controls, it was found that mTBI patients had significant increases in symptoms such as headaches, sore eyes, words going in and out of focus, and losing place while reading [34]. Convergence insufficiency has also been reported to be associated with double vision, sleepiness, and losing concentration. However, many of these symptoms could also be due to headache disorders or other neurocognitive or psychiatric issues associated with mTBI and may not necessarily be indicative of, nor entirely explained by, convergence insufficiency in a given patient.

3.3. Saccades and smooth pursuit

Assessment of mild saccadic dysfunction and smooth pursuit at the bedside is challenging and requires clinical expertise. Most abnormalities with saccades and pursuit that occur with mTBI would be missed by a cursory clinical exam and determination of whether a saccade is abnormal can be challenging. Further, despite evidence of impaired saccade behavior detected by video-oculography [38,39] (described in more detail later), studies have shown that subjects with concussion did not have abnormalities of saccades on clinical examination. Nonetheless, in one prospective study it was found that 6/20 (30%) of patients with blast-related mTBI had saccadic dysfunction on clinical exam and 12/20 (60%) had an abnormality in pursuit whereas none of the 20 controls had an abnormality in either [34]. In a retrospective study of combat-related mTBI, it was found that 23.4% of patients had saccadic or pursuit dysfunction [35].

3.4. Other visual abnormalities

Patients with mild TBI commonly have accommodative dysfunction, or abnormalities in the ability of the eye to change optical power in order to maintain a focused image as the distance varies. Capo-Aponte and colleagues prospectively found that 65% of blast-related mTBI patients versus 15% of controls had abnormalities in accommodative amplitude. Patients with mTBI have also less commonly been found to have accommodative infacility, or transient blurring due to a slowness in the eyes' ability to move from one level of accommodation to another [34].

Increased light sensitivity is also very common after concussion, possibly due to meningeal irritation or disordered thalamic processing [40]. In one study, contact lens wear, but not tinted glasses, was found to improve light sensitivity, suggesting that it may be best to allow natural adaptation [41].

4. Eye movement abnormalities in concussion: the eye movement laboratory

The ocular motor system in concussed patients can be assessed directly using quantified eye movement recordings, such as video-oculography, and indirectly with performance measures that incorporate eye movements.

4.1. Saccades

Saccadic generation involves complex cognitive processes including an assessment of the stimulus, as well as goals and intentions [42]. For saccade generation, the visuospatial information from the stimulus is relayed from the occipital lobe and processed in the posterior parietal cortex. Saccades are then generated and executed in frontal and parietal lobe saccade centers, including frontal eye fields (FEF), the dorsolateral prefrontal cortex (DLPFC), the supplementary motor area (SMA), the cingulate eye field (CEF), and parietal eye fields (PEF) [39,42–55] (see Fig. 1). The diffuse nature and complexity of this network render it susceptible to injury in mTBI.

Eye movement recordings allow multiple features of saccades to be recorded, such as latency (time between target onset and saccade onset), velocity, amplitude, duration, accuracy, directional errors, and positional errors. In the laboratory, saccade behavior can be altered by manipulating the timing of onset and offset of saccade visual targets and fixation. In the laboratory, therefore, many saccade types can be used to probe specific aspects of brain functioning, including higher cognitive functions (see Table 2). A few saccade types have been heavily utilized in mTBI research. These saccade types, and a simplified schema of cortical structures involved in specific deficits, are summarized in Tables 3 and 4. Self-paced saccades are volitional saccades performed by having the subject look back and forth between two points as rapidly as possible without verbal commands. Anti-saccades, which are performed by having the subject look in the direction opposite to a stimulus, require inhibition of reflexive saccades to the target and generation of volitional saccades in the opposite direction. Anti-saccades, thus, carry a high cognitive load. Memory-guided saccades are tested by generation of saccades to a remembered location of a previously displayed visual target when the target is no longer visible.

Patients with acute mTBI have been found to have impairments in memory-guided saccades and anti-saccades, with increased saccadic latencies, higher directional errors, and poorer spatial accuracy (Table 5) [34,38,39,56–58]. Longer intervals between saccades, and generation of a smaller number of saccades, have been found in tests of self-paced saccades [39]. Patients with prolonged post-concussive symptoms 3–5 months after mTBI also have been shown to have impairments in anti-saccades, memory-guided saccades, and self-paced saccades, when compared with patients who recovered well [59]. Patients with chronic symptoms greater than 6 months after mTBI had similarly impaired results, and it was found that these eye movement tests were more sensitive for deficit detection than neuropsychological evaluation [60].

Abnormalities in saccadic tests appear to normalize once patients recover in terms of their post-concussive symptoms [59], but further studies are needed to characterize the exact time course of the eye movement abnormalities. A detailed assessment of saccades using video-oculography in concussed patients allows one to quantitate and further localize injury in patients with visual symptoms, provides an objective correlate to acute and chronic symptomatology associated with mTBI, may potentially be used as outcome measures in clinical trials, and potentially could be used to monitor recovery.

4.2. Smooth pursuit

Abnormalities with predictive visual tracking have been reported in patients with mTBI using video-oculography. Smooth pursuit of a predictive target is coordinated by the cerebellum based on input from the retina, as well as higher cortical input [61,62]. Predictive visual tracking requires attention, anticipation, and working memory, and involves smooth as well as saccadic movements at times to maintain gaze on a target [63].

Using a circular tracking test in which a target moves at a fixed rate and may or may not be temporarily extinguished, Suh and colleagues found that mTBI patients had impaired target prediction with increased eye position error and variability of eye position versus controls [64].

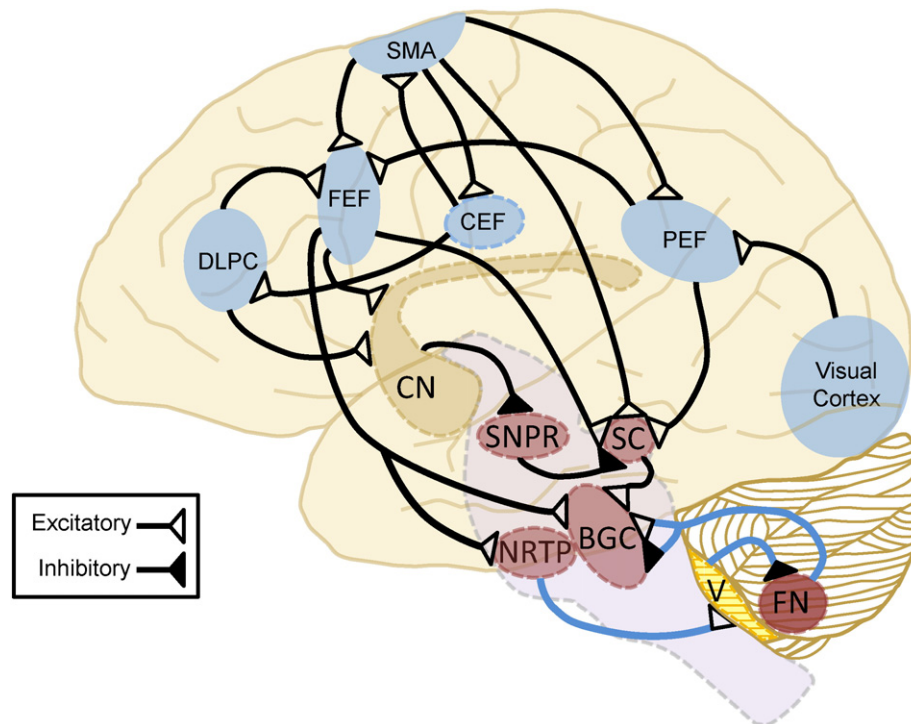


Fig. 1. Major cortical and subcortical pathways involved in saccadic generation. In the direct pathway, saccades are initiated when the frontal eye field (FEF), parietal eye field (PEF), or supplementary motor area sends signals to the superior colliculus (SC) which then projects to the brainstem gaze centers (BGC). In parallel, the FEF also initiates saccades via direct connections to the BGC. The cingulate eye field (CEF) sends signals to the other eye fields in the frontal lobe. In the indirect pathway, the FEF via the caudate (CN) inhibits the substantia nigra pars reticulata (SNPR), thereby inhibiting the SNPR's inhibition of the SC and allowing saccade generation. In general terms, the FEF generates voluntary or memory guided saccades, the PEF is involved in reflexive saccades, the SMA produces saccades in coordination with body movements as well as successive saccades, the CEF generates intentional saccades and saccades that occur when shifting attention, and the dorsolateral prefrontal cortex (DLPC) is involved in anti-saccades, the inhibition of reflexive saccades, and anticipatory saccades. Lesions in cerebellar projections (shown in blue) can lead to saccadic dysmetria. The cerebellar oculomotor vermis (V) receives projections from the nucleus reticularis tegmenti pontis (NRTP) and then inhibits the ipsilateral caudal fastigial nucleus (FN), which then projects to the BGC to enhance saccades moving to the contralateral side and lessen saccades moving to the ipsilateral side, likely via both inhibitory and excitatory connections.

The differences between patients with mTBI and controls was more robust when the target was temporarily extinguished, which requires a greater extent of predictive tracking [64,65]. The abnormalities with smooth pursuit correlated with scores of attention and executive function on the California Verbal Learning Test [64]. The above smooth pursuit studies were performed in the acute setting, within 10 days of mTBI, as well as in the chronic setting, with testing performed an average of 2.3 years after mTBI. There were no differences between the two groups [64]. Further studies are necessary to clarify whether these abnormalities in pursuit are maintained concurrently with post-concussive symptoms or beyond resolution.

4.3. Video-oculography correlations with MRI

Eye movement abnormalities have been found to correlate with MRI changes in mTBI patients. Maruta and colleagues found that variability of eye position in a circular tracking test in chronic TBI patients corresponded with abnormal mean fractional anisotropy (FA) values on DTI in several regions, including the right anterior corona radiata, the left superior cerebellar peduncle, and the genu of the corpus

Table 2

Selected higher cortical functions and corresponding tests of eye movements that can be used to probe those functions.

Higher cognitive function	Eye movement tests
Attention	Smooth pursuit of a predictive target
Executive function	Anti-saccades
Memory	Memory-guided saccades Smooth pursuit of a predictive target

collosum [66]. Johnson and colleagues used video-oculography to assess eye movements with simultaneous fMRI in 9 concussed patients within 7 days of injury and in 9 healthy controls [58]. While undergoing fMRI, the subjects performed fixation, reflexive saccades, anti-saccades, memory-guided saccades, self-paced saccades, and smooth pursuit. Similar to other eye movement studies, they found that concussed subjects did significantly worse on antisaccade, memory-guided saccade, and self-paced saccade tasks, with longer latencies, lower accuracy, higher error rates, increased position errors, and decreased number of self-paced saccades. Increased activation in several brain regions was identified on fMRI. For antisaccade and self-paced saccade tasks, there was increased activation in the cerebellum and visual cortices in concussed subjects versus controls. For self-paced saccades there was also increased activation in bilateral DLPC, among other regions. For the memory-guided saccade task, there was increased activation of the left hippocampus, right lingual gyrus, left precentral gyrus,

Table 3

Examples of Saccade Subtypes.

Saccade subtype	Description
Memory-guided saccades	Volitional saccades generated to the remembered location of a previously displayed visual target when the target is no longer visible.
Antisaccades	Volitional saccades generated in the direction opposite to a visual target, which requires suppressing a saccade to the visual target.
Self-paced saccades	Volitional saccades made between two continuously present targets without verbal commands.
Reflexive visually-guided saccades	Saccades involuntarily generated to an unexpected novel visual target

Table 4

Simplified schema of the role of cortical structures in saccade subtype deficits. Abbreviations: FEF—frontal eye fields, DLPC—dorsolateral prefrontal cortex, PPC—posterior parietal cortex, SMA—supplementary motor area, CEF—cingulate eye field, SC—superior colliculus, PEF—parietal eye fields.

Saccade subtype	Cortical structures involved per studies with functional deficits in the saccade subtype
Memory-guided saccades [43,46,51–53]	FEF and DLPC lesions reduce accuracy and increase response errors. DLPC and PPC are reciprocally connected - lesions in either affect memory-guided saccades. Lesions in SMA cause errors in sequences of memory-guided saccades.
Antisaccades [38,44,45,47,49]	FEF triggers the antisaccade away from the target. DLPC inhibits a reflexive saccade to the target presented. Lesions of CEF lead to deficits in antisaccades, likely through connections to DLPC and FEF.
Self-paced saccades [38,54]	Deficits thought due to FEF lesions or lesions in connections between FEF or DLPC and SC.
Reflexive visually-guided saccades [50]	Increased latency of reflexive visually-guided saccades with PEF lesions.

cerebellum, left frontal eye fields, precuneus, and brainstem. Although the concussed group did not do appreciably worse on the simple saccade and pursuit tasks, there nonetheless was increased activation on fMRI while performing the tasks versus controls, suggesting the possibility that there is a compensatory mechanism to maintain functional performance in the face of slight deficits in the networks. The authors performed a follow-up study of 7 concussed patients at 30 days post-injury versus controls and found continued impairments in ocular motor function on complicated tasks and increased activation on fMRI, though the results were not as marked as in the acute study [67]. These studies highlight a possible anatomic correlate of the ocular motor abnormalities in the mTBI patients, and reinforce that mTBI can affect diffuse networks in the brain that can be captured through tests of eye movements.

5. Eye movement abnormalities in concussion: the sidelines

5.1. Portable video-oculography

Laboratory based studies highlighting eye movement changes in mTBI currently are limited by challenges related to portability, thus impeding global capture of this information on the sidelines. Portable, head mounted video-based eye trackers will be necessary for use on the sidelines, and such have been studied in the research setting on a limited basis. Cifu and colleagues used a portable eye tracking device on 60 military subjects with persistent concussive symptoms versus 26 controls [68]. Concussed subjects had impaired ability to track stepped and smoothly moving targets in comparison to controls. Those with concussive symptoms had larger saccadic position errors, smaller saccadic amplitudes, smaller predicted peak velocities, smaller peak accelerations and also abnormalities in pursuit velocities [68]. A small study of 12 boxers undergoing 'saccadometry' with a portable ringside device capture saccade latencies within 7 min of a match and demonstrated latency prolongation that resolved within days [69]. Further work is needed to determine how acutely these changes occur and how widely available and applicable these techniques may be at the sidelines.

5.2. King-Devick (K-D) test for sideline assessment

While direct recording of eye movements has not yet been thoroughly studied for sideline assessment of sports-related concussion and may prove too cumbersome, time consuming, or challenging to interpret, the K-D test allows a rapid, reliable, and objective assessment that incorporates eye movements. This test requires that the subject read numbers with variable spacing on three test cards as quickly as

possible. The total time required in seconds for the three cards is the score, and the test takes about 1–2 min to perform. Performing the K-D test involves saccades, attention, and language and thus evaluates diffuse networks in the brain, including the networks for saccade generation in the brainstem, cerebellum, and areas of the cerebral cortex such as the DLPC, frontal eye fields, supplementary motor area, and parietal lobes [70,71]. Worsening from baseline is consistent with the diagnosis of concussion, since in healthy athletes the scores typically improve with practice and are not adversely affected by physical activity [70–75]. In a meta-analysis of 15 studies evaluating the ability of the K-D test to detect concussions in a variety of sports including hockey, lacrosse, football, basketball, soccer boxing, and rugby, the K-D test was found to have a sensitivity of 86% and a specificity of 90% [76]. In this meta-analysis, the K-D test was found to worsen on average 4.8 s from baseline in the setting on concussion. The most commonly used tests for detecting concussions on the sidelines are the Standardized Assessment of Concussion (SAC) and Balance Error Scoring System (BESS), but these tests do not include an assessment of eye movements. The SAC and BESS combined missed 10% of 20 captured concussions. With inclusion of the K-D, all concussions were captured [77]. Moreover, in another study, it was found that the K-D had the greatest capacity to distinguish the 12 concussed athletes from 14 controls when compared with a timed tandem-gait balance test and the SAC [78]. Thus multiple lines of evidence have emerged to show that this test incorporating eye movements, the K-D test, is sensitive and specific in detecting concussions on the sidelines and complements tests of balance and the SAC as a performance measure.

6. Complex visuomotor tasks for return to play

Given the complexities of visuomotor integration necessary for sports activities, and the subtle changes in ocular motor function that occur with concussion, an evaluation of concussed athletes during complicated visuomotor tasks may be helpful for return to play decisions. It has been found that those athletes who have poor performance on tasks such as depth perception and visual reaction time were found to have more severe and a higher number of impacts as detected using head impact telemetry [79], thus underlining the need to assess for such complex visuomotor tasks. One paper found that many athletes who have been cleared for return to play based on resolution of physical symptoms, nonetheless, had abnormalities when performing a task which involved walking through or around a gap of variable diameter, which required visually assessing the gap relative to their own size [80]. Other complex tasks on the horizon which require further evaluation include pairing a hand-eye coordination task with a balance task [81] and visuomotor pointing tasks on a computer screen [82].

Perhaps more sensitive for ongoing abnormalities would be a combination of a complex task with ocular motor recordings. Murray and colleagues assessed the ocular motor system during a balance task in 9 concussed patients versus 9 healthy controls by having the subjects wear a monocular tracking device while subjects played the WiiFit Soccer heading game with the instructions to maintain their gaze in the center of the screen [83]. Whereas they found that those with the prior concussion had increased deviations from the central fixation point, there was no difference in performance on the task in comparison to controls. For those with a prior concussion, performance on the Wii game was negatively correlated with the percentage of time on the central fixation point ($r = -0.846$, $p = 0.004$). In contrast, for controls, performance on the Wii game was positively correlated with the percentage of time on the central fixation point ($r = 0.792$, $p = 0.011$). This suggests, in part, that the deviation from central fixation may be a compensatory mechanism, and it is unclear whether a more complex task may overwhelm the compensatory abilities. Clearly much more work is necessary.

Table 5
Saccades and pursuit in mild TBI (mTBI).

Study	Number of subjects	Time since injury	Memory-guided saccades	Anti-saccades	Self-paced saccades	Simple reflexive saccades	Tracking a circular target
Crevits (2000) [57]	25 mTBI – no alcohol 6 mTBI – alcohol 27 controls	Within 24 h	↑ Latency and errors only in mTBI with alcohol	↑ Latency and errors only in mTBI with alcohol			
Heitger (2002) [38]	30 mTBI 30 controls	Within 9 days	↑ Latency and errors ^a				
Heitger (2004) [39]	28 mTBI 28 controls	Within 16 days	↑ Errors ↓ Accuracy	↑ Latency and errors ↓ Accuracy	Longer inter-saccade intervals and fewer saccades	No difference	
Heitger (2006) [56]	37 mTBI 37 controls	1 week and 3, 6, and 12 months	Improved but ongoing deficits at all intervals	Improved but ongoing deficits at all intervals			
Suh (2006a,b) [64,65]	26 mTBI ^b 26 controls	Within 10 days or within 5 years ^b					↑ Eye position error ↓ Target prediction
Pearson (2007) [69]	12 boxers	7 min after match and days later				↑ Latency ^c but resolved within days	
Kraus (2007) [60]	20 mTBI 19 controls	Mean 65 months		↑ Errors		No difference	
Heitger (2009) [59]	36 PCS 36 prior mTBI with good recovery	3–5 months	PCS did worse ^d	PCS did worse	PCS did worse	No difference	
Johnson (2015a,b) [58,67]	9 mTBI ^e 9 controls	Within 7 days and 30 days	Acutely: ↑ Errors ↓ Accuracy 30 days: ↑ Errors	Acutely and 30 days: ↑ Errors ↓ Accuracy	Acutely and 30 days: Fewer saccades		No difference

PCS = post-concussive syndrome.

^a Memory-guided saccade sequences with 2–3 steps were tested, rather than single memory-guided saccades.

^b In the first study, 6 of the mTBI subjects tested within 10 days, 15 had PCS and were tested a mean of 2 years after injury. For the second study, the testing included blanking of the target, and there were an additional 5 subjects with PCS. There were no differences between the acute and PCS groups, so the results are grouped together.

^c Possibly different from Heitger (2004) and Kraus (2007) due to inter-subject vs. intra-subject comparisons.

^d Abnormal saccades of all types were more likely to be present in PCS with higher symptom burden.

^e 9 subjects in first study and 7 in follow-up study. Ocular motor testing was performed simultaneously with fMRI.

7. Conclusions and future directions

Eye movements incorporate diffuse and complex brain circuitry, in regions commonly affected by concussion, such as the frontal lobes. There may be abnormalities on clinical neuro-ophthalmological exam in concussion and detailed evaluation is necessary. In addition, tests incorporating eye movements are well poised to be a sensitive measure to diagnose and evaluate recovery from concussions and other forms of mTBI. Indeed, studies have repeatedly demonstrated that the King-Devick test is a sensitive and reliable method of sideline concussion detection, especially when used in conjunction with the SAC and BESS. Portable eye movement trackers require further investigation but hold promise in potentially assisting concussion detection and monitoring recovery. Detailed eye movement evaluation in the laboratory holds additional promise in assessing concussed patients and monitoring recovery. The eye movement evaluation could potentially be coupled with pupillometry [84,85] to improve the assessment of vision on the sidelines.

Concussions and sub-concussive repetitive brain impact, as may occur with contact sports, may cumulatively lead to subtle changes in brain morphology and function with uncertain long-term clinical consequences. Thus the burden is on researchers to develop sensitive and reliable tests for detecting even mild brain injury. The potential import of even sub-concussive repetitive brain impact is highlighted in one recent study which found not only changes in imaging as had been reported previously [5,6,15–17], but also changes on neurocognitive testing. It was found that a cohort of high school football players without any symptoms of concussion had deficits on neurocognitive testing primarily involving visual working memory with accompanying changes in the activation of the DLPC on fMRI which corresponded with impacts detected by HITS [7]. Given that DLPC is involved in inhibiting reflexive saccades, performing anticipatory saccades, and short-term spatial memory, deficits in DLPC functioning would be expected to impede performance on multiple eye movement tests [58,86], which thus may provide another means of assessing such sub-concussive injury. The King-Devick test is a simple eye movement test which likely involves DLPC functioning and also has been found to correlate with visual memory scores on neuropsychological testing [77]. Eye movement tests, perhaps in combination with complex visuomotor tasks, pupillometry, and/or imaging, are an excellent avenue for further exploration to help diagnose and manage patients with concussion.

References

- [1] W.P. Meehan III, L.J. Micheli, Concussion results in deficits in neurocognitive functioning. Preface, *Clin. Sports Med.* 30 (1) (Jan 2011) xvii–iii.
- [2] J.A. Langlois, W. Rutland-Brown, M.M. Wald, The epidemiology and impact of traumatic brain injury: a brief overview, *J. Head Trauma Rehabil.* 21 (5) (Sep-Oct 2006) 375–378.
- [3] J.A. Langlois, R.-B.W. Thomas, *Traumatic Brain Injury in the United States: Emergency Department Visits, Hospitalizations, and Deaths*, Centers for Disease Control and Prevention, National Center for Injury Prevention and Control, Atlanta (GA), 2004.
- [4] D.M. Torres, K.M. Galetta, H.W. Phillips, et al., Sports-related concussion: anonymous survey of a collegiate cohort, *Neurol. Clin. Pract.* 3 (4) (Aug 2013) 279–287.
- [5] T.W. McAllister, J.C. Ford, L.A. Flashman, et al., Effect of head impacts on diffusivity measures in a cohort of collegiate contact sport athletes, *Neurology* 82 (1) (Jan 7 2014) 63–69.
- [6] E.M. Davenport, C.T. Whitlow, J.E. Urban, et al., Abnormal white matter integrity related to head impact exposure in a season of high school varsity football, *J. Neurotrauma* 31 (19) (Oct 1 2014) 1617–1624.
- [7] T.M. Talavage, E.A. Nauman, E.L. Breedlove, et al., Functionally-detected cognitive impairment in high school football players without clinically-diagnosed concussion, *J. Neurotrauma* 31 (4) (Feb 15 2014) 327–338.
- [8] Concussion (mild traumatic brain injury) and the team physician: a consensus statement, *Med. Sci. Sports Exerc.* 38 (2) (Feb 2006) 395–399.
- [9] P. McCrory, K. Johnston, W. Meeuwisse, et al., Summary and agreement statement of the 2nd International Conference on Concussion in Sport, Prague 2004, *Clin. J. Sport Med.* 15 (2) (Mar 2005) 48–55.
- [10] D.J. Sharp, P.O. Jenkins, Concussion is confusing us all, *Pract. Neurol.* 15 (3) (Jun 2015) 172–186.
- [11] D.T. Pulsipher, R.A. Campbell, R. Thoma, J.H. King, A critical review of neuroimaging applications in sports concussion, *Curr. Sports Med. Rep.* 10 (1) (Jan-Feb 2011) 14–20.
- [12] T. Sasaki, O. Pasternak, M. Mayinger, et al., Hockey Concussion Education Project, Part 3. White matter microstructure in ice hockey players with a history of concussion: a diffusion tensor imaging study, *J. Neurosurg.* 120 (4) (Apr 2014) 882–890.
- [13] E.J. Grossman, J.H. Jensen, J.S. Babb, et al., Cognitive impairment in mild traumatic brain injury: a longitudinal diffusional kurtosis and perfusion imaging study, *AJNR, Am. J. Neuroradiol.* 34 (5) (May 2013) 951–957 951–953.
- [14] E. Chamard, H. Theoret, E.N. Skopelja, L.A. Forwell, A.M. Johnson, P.S. Echlin, A prospective study of physician-observed concussion during a varsity university hockey season: metabolic changes in ice hockey players. Part 4 of 4, *Neurosurg. Focus* 33 (6) (Dec 2012) 1–7 (E4).
- [15] J.J. Bazarian, T. Zhu, J. Zhong, et al., Persistent, long-term cerebral white matter changes after sports-related repetitive head impacts, *PLoS One* 9 (4) (2014), e94734.
- [16] K. Abbas, T.E. Shenk, V.N. Poole, et al., Alteration of default mode network in high school football athletes due to repetitive subconcussive mild traumatic brain injury: a resting-state functional magnetic resonance imaging study, *Brain Connect.* 5 (2) (Apr 2015) 91–101.
- [17] K. Abbas, T.E. Shenk, V.N. Poole, et al., Effects of repetitive sub-concussive brain injury on the functional connectivity of Default Mode Network in high school football athletes, *Dev. Neuropsychol.* 40 (1) (Jan 2015) 51–56.
- [18] K.M. Guskiewicz, N.L. Weaver, D.A. Padua, W.E. Garrett Jr., Epidemiology of concussion in collegiate and high school football players, *Am. J. Sports Med.* 28 (5) (Sep-Oct 2000) 643–650.
- [19] D.F. Meaney, D.H. Smith, Biomechanics of concussion, *Clin. Sports Med.* 30 (1) (Jan 2011) 19–31 vii.
- [20] B.P. Boden, R.L. Tacchetti, R.C. Cantu, S.B. Knowles, F.O. Mueller, Catastrophic head injuries in high school and college football players, *Am. J. Sports Med.* 35 (7) (Jul 2007) 1075–1081.
- [21] M.E. Halstead, K.D. Walter, Council on Sports M, Fitness. American Academy of Pediatrics. Clinical report—sport-related concussion in children and adolescents, *Pediatrics* 126 (3) (Sep 2010) 597–615.
- [22] A. Sim, L. Terryberry-Spohr, K.R. Wilson, Prolonged recovery of memory functioning after mild traumatic brain injury in adolescent athletes, *J. Neurosurg.* 108 (3) (Mar 2008) 511–516.
- [23] B.E. Gavett, R.C. Cantu, M. Shenton, et al., Clinical appraisal of chronic traumatic encephalopathy: current perspectives and future directions, *Curr. Opin. Neurol.* 24 (6) (Dec 2011) 525–531.
- [24] D.J. Felleman, D.C. Van Essen, Distributed hierarchical processing in the primate cerebral cortex, *Cereb. Cortex* 1 (1) (Jan-Feb 1991) 1–47.
- [25] N.C. Nevin, Neuropathological changes in the white matter following head injury, *J. Neuropathol. Exp. Neurol.* 26 (1) (Jan 1967) 77–84.
- [26] M.L. Lipton, N. Kim, Y.K. Park, et al., Robust detection of traumatic axonal injury in individual mild traumatic brain injury patients: intersubject variation, change over time and bidirectional changes in anisotropy, *Brain Imaging Behav.* 6 (2) (Jun 2012) 329–342.
- [27] J. Maruta, S.W. Lee, E.F. Jacobs, J. Ghajar, A unified science of concussion, *Ann. N. Y. Acad. Sci.* 1208 (Oct 2010) 58–66.
- [28] A. Dhaliwal, A.L. West, J.D. Trobe, D.C. Musch, Third, fourth, and sixth cranial nerve palsies following closed head injury, *J. Neuroophthalmol.* 26 (1) (Mar 2006) 4–10.
- [29] F.E. Lepore, Disorders of ocular motility following head trauma, *Arch. Neurol.* 52 (9) (Sep 1995) 924–926.
- [30] G.P. Van Stavern, V. Biousse, M.J. Lynn, D.J. Simon, N.J. Newman, Neuro-ophthalmic manifestations of head trauma, *J. Neuroophthalmol.* 21 (2) (Jun 2001) 112–117.
- [31] J.S. Elston, Traumatic third nerve palsy, *Br. J. Ophthalmol.* 68 (8) (Aug 1984) 538–543.
- [32] K.A. Walter, N.J. Newman, S. Lessell, Oculomotor palsy from minor head trauma: initial sign of intracranial aneurysm, *Neurology* 44 (1) (Jan 1994) 148–150.
- [33] A.F. Coello, A.G. Canals, J.M. Gonzalez, J.J. Martin, Cranial nerve injury after minor head trauma, *J. Neurosurg.* 113 (3) (Sep 2010) 547–555.
- [34] J.E. Capo-Aponte, T.G. Urosevich, L.A. Temme, A.K. Tarbett, N.K. Sanghera, Visual dysfunctions and symptoms during the subacute stage of blast-induced mild traumatic brain injury, *Mil. Med.* 177 (7) (Jul 2012) 804–813.
- [35] K.D. Brahm, H.M. Wilgenburg, J. Kirby, S. Ingalla, C.Y. Chang, G.L. Goodrich, Visual impairment and dysfunction in combat-injured servicemembers with traumatic brain injury, *Optom. Vis. Sci.* 86 (7) (Jul 2009) 817–825.
- [36] C.L. Master, M. Scheiman, M. Galloway, et al., Vision diagnoses are common after concussion in adolescents, *Clin. Pediatr.* (Jul 7 2015) <http://dx.doi.org/10.1177/000922815594367>.
- [37] D. Szymanowicz, K.J. Ciuffreda, P. Thiagarajan, D.P. Ludlam, W. Green, N. Kapoor, Vergence in mild traumatic brain injury: a pilot study, *J. Rehabil. Res. Dev.* 49 (7) (2012) 1083–1100.
- [38] M.H. Heitger, T.J. Anderson, R.D. Jones, Saccade sequences as markers for cerebral dysfunction following mild closed head injury, *Prog. Brain Res.* 140 (2002) 433–448.
- [39] M.H. Heitger, T.J. Anderson, R.D. Jones, J.C. Dalrymple-Alford, C.M. Frampton, M.W. Ardagh, Eye movement and visuomotor arm movement deficits following mild closed head injury, *Brain* 127 (Pt 3) (Mar 2004) 575–590.
- [40] E. Singman, Automating the assessment of visual dysfunction after traumatic brain injury, *Med. Instrum.* (2013).
- [41] J.Q. Truong, K.J. Ciuffreda, M.H. Han, I.B. Suchoff, Photosensitivity in mild traumatic brain injury (mTBI): a retrospective analysis, *Brain Inj.* 28 (10) (2014) 1283–1287.
- [42] S.B. Hutton, Cognitive control of saccadic eye movements, *Brain Cogn.* 68 (3) (Dec 2008) 327–340.
- [43] R.J. Leigh, D.S. Zee, *The Neurology of Eye Movements*, 5th edition (2015).
- [44] B. Gaymard, C. Pierrrot-Deseilligny, S. Rivaud, Impairment of sequences of memory-guided saccades after supplementary motor area lesions, *Ann. Neurol.* 28 (5) (Nov 1990) 622–626.

- [45] B. Gaymard, C.J. Ploner, S. Rivaud-Pechoux, C. Pierrot-Deseilligny, The frontal eye field is involved in spatial short-term memory but not in reflexive saccade inhibition. *Experimental brain research. Experimentelle Hirnforschung, Exp. Cereb.* 129 (2) (Nov 1999) 288–301.
- [46] D. Milea, S. Lehericy, S. Rivaud-Pechoux, et al., Antisaccade deficit after anterior cingulate cortex resection, *Neuroreport* 14 (2) (Feb 10 2003) 283–287.
- [47] R.M. Muri, A.I. Vermersch, S. Rivaud, B. Gaymard, C. Pierrot-Deseilligny, Effects of single-pulse transcranial magnetic stimulation over the prefrontal and posterior parietal cortices during memory-guided saccades in humans, *J. Neurophysiol.* 76 (3) (Sep 1996) 2102–2106.
- [48] T. Nyffeler, R.M. Muri, Y. Bucher-Ottiger, C. Pierrot-Deseilligny, B. Gaymard, S. Rivaud-Pechoux, Inhibitory control of the human dorsolateral prefrontal cortex during the anti-saccade paradigm—a transcranial magnetic stimulation study, *Eur. J. Neurosci.* 26 (5) (Sep 2007) 1381–1385.
- [49] C. Pierrot-Deseilligny, Cortical control of saccades in man, *Acta Neurol. Belg.* 91 (2) (1991) 63–79.
- [50] C. Pierrot-Deseilligny, R.M. Muri, C.J. Ploner, B. Gaymard, S. Demeret, S. Rivaud-Pechoux, Decisional role of the dorsolateral prefrontal cortex in ocular motor behaviour, *Brain* 126 (Pt 6) (Jun 2003) 1460–1473.
- [51] C. Pierrot-Deseilligny, S. Rivaud, B. Gaymard, Y. Agid, Cortical control of reflexive visually-guided saccades, *Brain* 114 (Pt 3) (Jun 1991) 1473–1485.
- [52] C. Pierrot-Deseilligny, S. Rivaud, B. Gaymard, Y. Agid, Cortical control of memory-guided saccades in man. *Experimental brain research. Experimentelle Hirnforschung, Exp. Cereb.* 83 (3) (1991) 607–617.
- [53] S.A. Brandt, C.J. Ploner, B.U. Meyer, S. Leistner, A. Villringer, Effects of repetitive transcranial magnetic stimulation over dorsolateral prefrontal and posterior parietal cortex on memory-guided saccades. *Experimental brain research. Experimentelle Hirnforschung, Exp. Cereb.* 118 (2) (Jan 1998) 197–204.
- [54] M.V. Chafee, P.S. Goldman-Rakic, Inactivation of parietal and prefrontal cortex reveals interdependence of neural activity during memory-guided saccades, *J. Neurophysiol.* 83 (3) (Mar 2000) 1550–1566.
- [55] I.M. Williams, J.L. Ponsford, K.L. Gibson, L.E. Mulhall, C.A. Curran, L.A. Abel, Cerebral control of saccades and neuropsychological test results after head injury, *J. Clin. Neurosci.* 4 (2) (Apr 1997) 186–196.
- [56] M.H. Heitger, R.D. Jones, J.C. Dalrymple-Alford, C.M. Frampton, M.W. Ardagh, T.J. Anderson, Motor deficits and recovery during the first year following mild closed head injury, *Brain Inj.* 20 (8) (Jul 2006) 807–824.
- [57] L. Crevits, M.C. Hanse, P. Tummers, G. Van Maele, Antisaccades and remembered saccades in mild traumatic brain injury, *J. Neurol.* 247 (3) (Mar 2000) 179–182.
- [58] B. Johnson, K. Zhang, M. Hallett, S. Slobounov, Functional neuroimaging of acute oculomotor deficits in concussed athletes, *Brain Imaging Behav.* 9 (3) (Sep 2015) 564–573.
- [59] M.H. Heitger, R.D. Jones, A.D. Macleod, D.L. Snell, C.M. Frampton, T.J. Anderson, Impaired eye movements in post-concussion syndrome indicate suboptimal brain function beyond the influence of depression, malingering or intellectual ability, *Brain* 132 (Pt 10) (Oct 2009) 2850–2870.
- [60] M.F. Kraus, D.M. Little, A.J. Donnell, J.L. Reilly, N. Simonian, J.A. Sweeney, Oculomotor function in chronic traumatic brain injury, *Cogn. Behav. Neurol.* 20 (3) (Sep 2007) 170–178.
- [61] K. Fukushima, T. Yamanobe, Y. Shinmei, J. Fukushima, S. Kurkin, B.W. Peterson, Coding of smooth eye movements in three-dimensional space by frontal cortex, *Nature* 419 (6903) (Sep 12 2002) 157–162.
- [62] G.T. Liu, N.J. Volpe, S. Galetta, *Neuro-Ophthalmology: Diagnosis and Management*, second ed. Saunders Elsevier, Philadelphia, 2010 551–554.
- [63] G.R. Barnes, Cognitive processes involved in smooth pursuit eye movements, *Brain Cogn.* 68 (3) (Dec 2008) 309–326.
- [64] M. Suh, R. Kolster, R. Sarkar, et al., Deficits in predictive smooth pursuit after mild traumatic brain injury, *Neurosci. Lett.* 401 (1–2) (Jun 19 2006) 108–113.
- [65] M. Suh, S. Basu, R. Kolster, et al., Increased oculomotor deficits during target blanking as an indicator of mild traumatic brain injury, *Neurosci. Lett.* 410 (3) (Dec 27 2006) 203–207.
- [66] J. Maruta, M. Suh, S.N. Niogi, P. Mukherjee, J. Ghajar, Visual tracking synchronization as a metric for concussion screening, *J. Head Trauma Rehabil.* 25 (4) (Jul-Aug 2010) 293–305.
- [67] B. Johnson, M. Hallett, S. Slobounov, Follow-up evaluation of oculomotor performance with fMRI in the subacute phase of concussion, *Neurology* 85 (13) (Sep 29 2015) 1163–1166.
- [68] D.X. Gifu, J.R. Wares, K.W. Hoke, P.A. Wetzel, G. Gitche, W. Carne, Differential eye movements in mild traumatic brain injury versus normal controls, *J. Head Trauma Rehabil.* 30 (1) (Jan-Feb 2015) 21–28.
- [69] B.C. Pearson, K.R. Armitage, C.W. Horner, R.H. Carpenter, Saccadometry: the possible application of latency distribution measurement for monitoring concussion, *Br. J. Sports Med.* 41 (9) (Sep 2007) 610–612.
- [70] K.M. Galetta, L.E. Brandes, K. Maki, et al., The King–Devick test and sports-related concussion: study of a rapid visual screening tool in a collegiate cohort, *J. Neurol. Sci.* 309 (1–2) (Oct 15 2011) 34–39.
- [71] K.M. Galetta, J. Barrett, M. Allen, et al., The King–Devick test as a determinant of head trauma and concussion in boxers and MMA fighters, *Neurology* 76 (17) (Apr 26 2011) 1456–1462.
- [72] D. King, T. Clark, C. Gissane, Use of a rapid visual screening tool for the assessment of concussion in amateur rugby league: a pilot study, *J. Neurol. Sci.* 320 (1–2) (Sep 15 2012) 16–21.
- [73] M.S. Galetta, K.M. Galetta, J. McCrossin, et al., Saccades and memory: baseline associations of the King–Devick and SCAT2 SAC tests in professional ice hockey players, *J. Neurol. Sci.* 328 (1–2) (May 15 2013) 28–31.
- [74] D. King, C. Gissane, P.A. Hume, M. Flaws, The King–Devick test was useful in management of concussion in amateur rugby union and rugby league in New Zealand, *J. Neurol. Sci.* 351 (1–2) (Apr 15 2015) 58–64.
- [75] D. King, P. Hume, C. Gissane, T. Clark, Use of the King–Devick test for sideline concussion screening in junior rugby league, *J. Neurol. Sci.* 357 (1–2) (Oct 15 2015) 75–79.
- [76] K.M. Galetta, M. Liu, D.F. Leong, R.E. Ventura, S.L. Galetta, L.J. Balcer, The King–Devick test of rapid number naming for concussion detection: meta-analysis and systematic review of the literature, *Concussion* (2015) <http://dx.doi.org/10.2217/cnc.15.8>.
- [77] Z. Marinides, K.M. Galetta, C.N. Andrews, et al., Vision testing is additive to the sideline assessment of sports-related concussion, *Neurol. Clin. Pract.* (2014).
- [78] D.F. Leong, L.J. Balcer, S.L. Galetta, G. Evans, M. Gimre, D. Watt, The King–Devick test for sideline concussion screening in collegiate football, *J. Optom.* 8 (2) (Apr-Jun 2015) 131–139.
- [79] J.A. Harpham, J.P. Mihalik, A.C. Littleton, B.S. Frank, K.M. Guskiewicz, The effect of visual and sensory performance on head impact biomechanics in college football players, *Ann. Biomed. Eng.* 42 (1) (Jan 2014) 1–10.
- [80] C.S. Baker, M.E. Cinelli, Visuomotor deficits during locomotion in previously concussed athletes 30 or more days following return to play, *Physiol. Rep.* 2 (12) (Dec 1 2014).
- [81] K. Bigsby, R.E. Mangine, J.F. Clark, et al., Effects of postural control manipulation on visuomotor training performance: comparative data in healthy athletes, *Int. J. Sports Phys. Ther.* 9 (4) (Aug 2014) 436–446.
- [82] J. Locklin, L. Bunn, E. Roy, J. Danckert, Measuring deficits in visually guided action post-concussion, *Sports Med.* 40 (3) (Mar 1 2010) 183–187.
- [83] N.G. Murray, V.N. Ambati, M.M. Contreras, A.P. Salvatore, R.J. Reed-Jones, Assessment of oculomotor control and balance post-concussion: a preliminary study for a novel approach to concussion management, *Brain Inj.* 28 (4) (2014) 496–503.
- [84] K. Mohan, H. Kecova, E. Hernandez-Merino, R.H. Kardon, M.M. Harper, Retinal ganglion cell damage in an experimental rodent model of blast-mediated traumatic brain injury, *Invest. Ophthalmol. Vis. Sci.* 54 (5) (May 2013) 3440–3450.
- [85] J. Capo-Aponte, T.G. Urosevich, D.V. Walsh, L.A. Temme, A.K. Tarbett, Pupillary light reflex as an objective biomarker for early identification of blast-induced TBI, *J. Spine S4* (2013).
- [86] S.D. Jamadar, J. Fielding, G.F. Egan, Quantitative meta-analysis of fMRI and PET studies reveals consistent activation in fronto-striatal-parietal regions and cerebellum during antisaccades and prosaccades, *Front. Psychol.* 4 (2013) 749.